

MEET THE FUTURE IN THE TREATMENT OF CANCER.....

*German Issue August 2001*

**EXOGEN-ELEKTRONIC-THERAPY (EET)**

**Concept EET : Dr. Hainz Meier / EXOGEN Medizintechnik AG / Regensburg**

45-year old patient. Medical examinations ( mammography, histology and sonography )  
Diagnosis: breast cancer on the right.

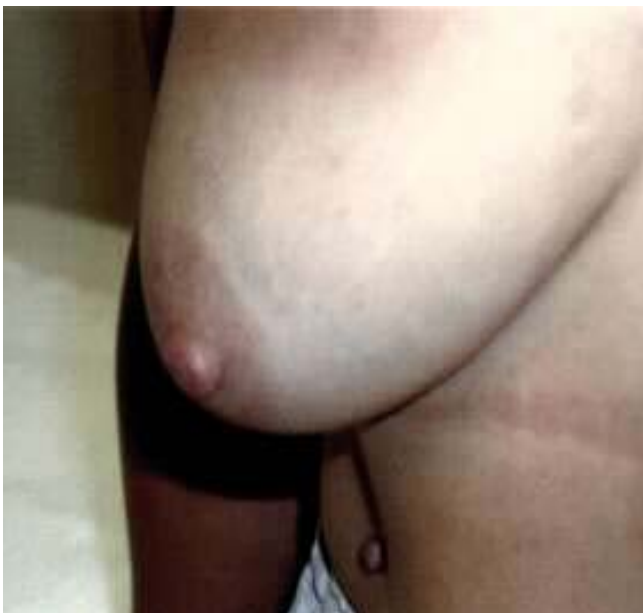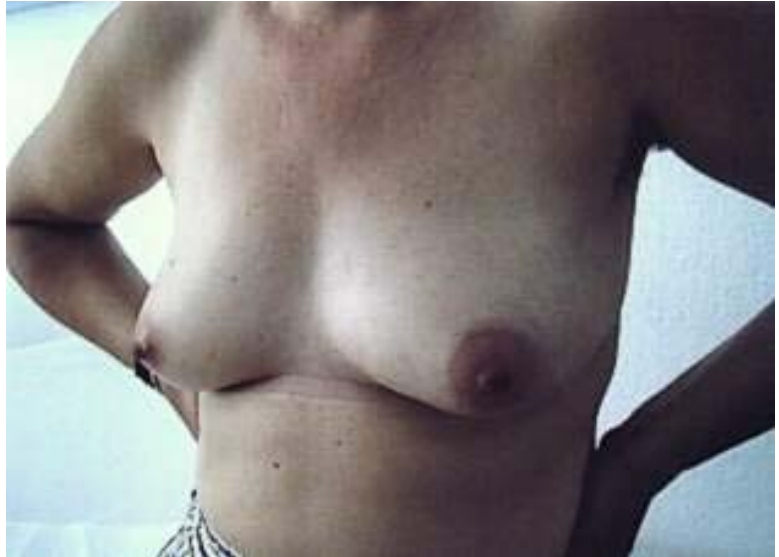**Histology before the treatment with Exogen-Galvano-Therapy:**

Invasien – lobular breast cancer, various focals one Carcinoma lobulare.

The pictures shows the patient two years after the treatment.  
Intotal the patient became 6 treatments.

**The result of controll examinations after two years: no findings.**

The patient is completely without symptoms.

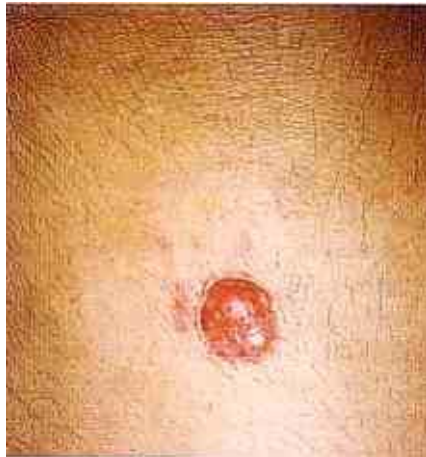

44-year old patient. Medical examinations: ( mammography and histology )  
Diagnosis: breast cancer

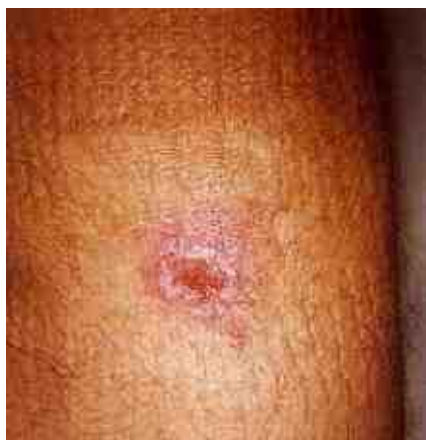The pictures shows the patient two years after the treatment. Intotal the patient became 5 treatments.

The breast is unharmed, she shows caudal a nearly visible scarred retraction.

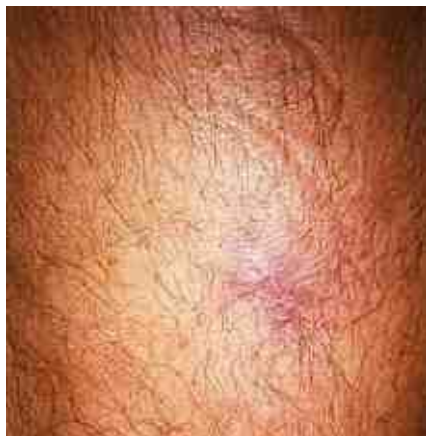All relevante bloodparameters are in the norm.



patient 50 years old  
Diagnosis:  
Basalioma thigh

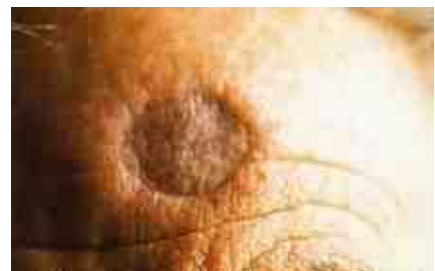

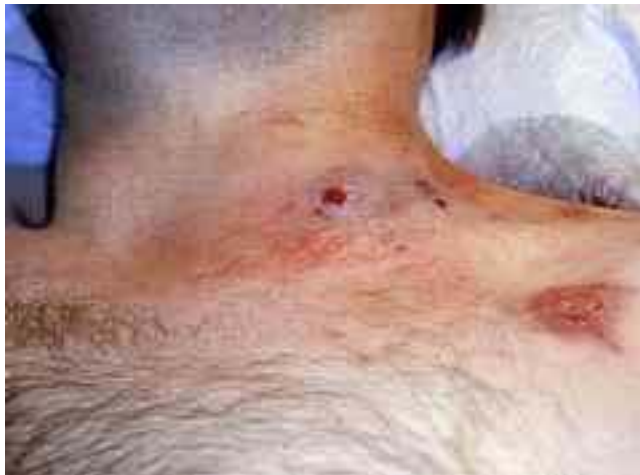The situation after nach  
**Exogen-Galvano-Therapy**  
10 V, 80 mA, 5 min.



Completely healing afer  
6 weeks.

This picture shows the cosmetic  
difference.  
**This ist the result of a  
tratditional surgical treatment**



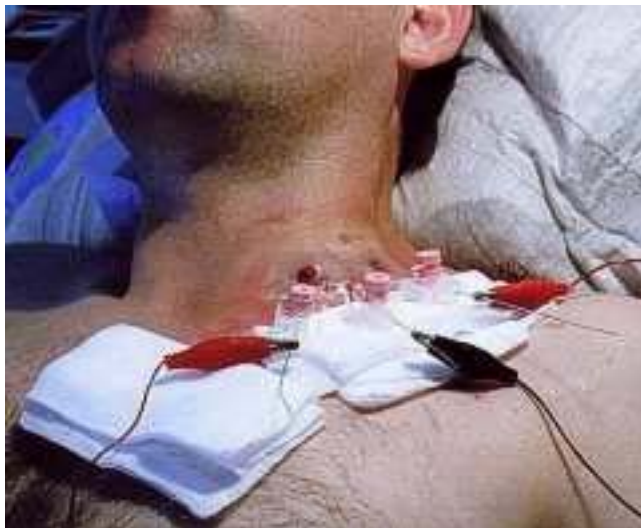

39-year old patient.

This picture shows a great supraclavicular metastasis of a malignant teratoma on the left side of the neck.

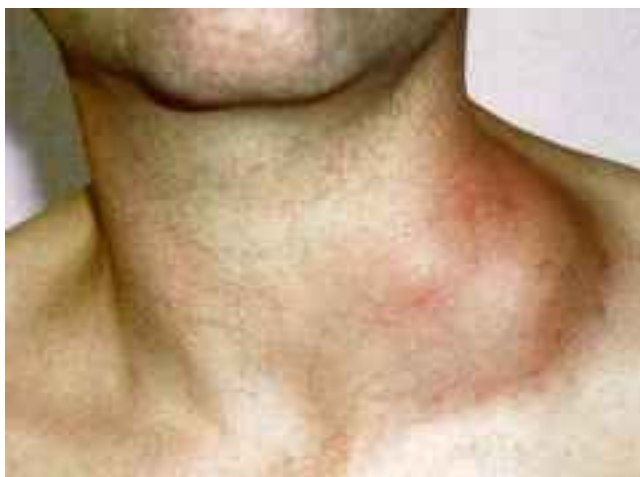The classification of the tumor: not operabel.

This ist the situation before the first of fife treatments with **Exogen-Galvano-Therapy**



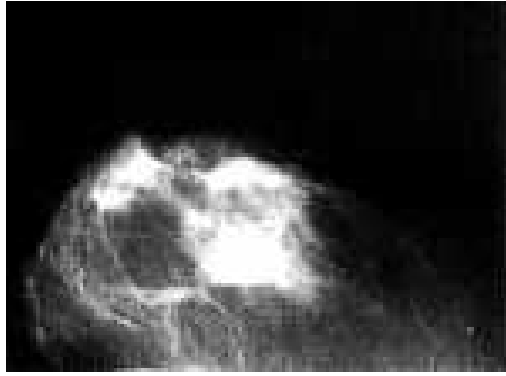
This picture shows the 3. of 5 treatments with 3 intratumoral recumbent elektrodes.

You see the conspicuous involution of the tumor.

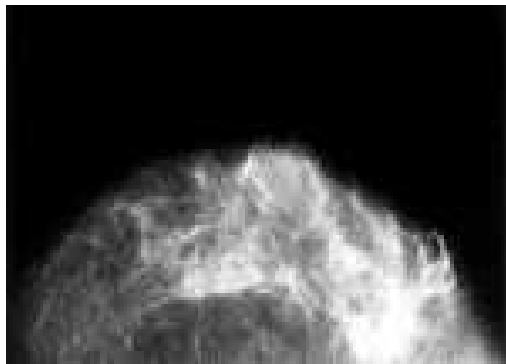


After 5 treatments with circa 5000 Coulomb we see the the completely involution of the tumor.

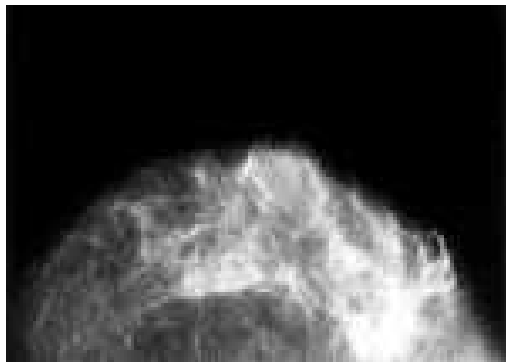
The patient is without symptoms.



1. Scirrhous cancer of the breast  
initial situation



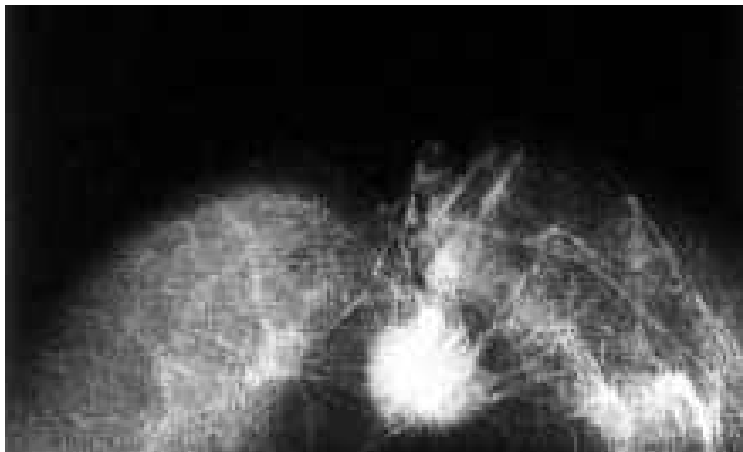
2. The situation after **Exogen-  
Galvano-Therapy**



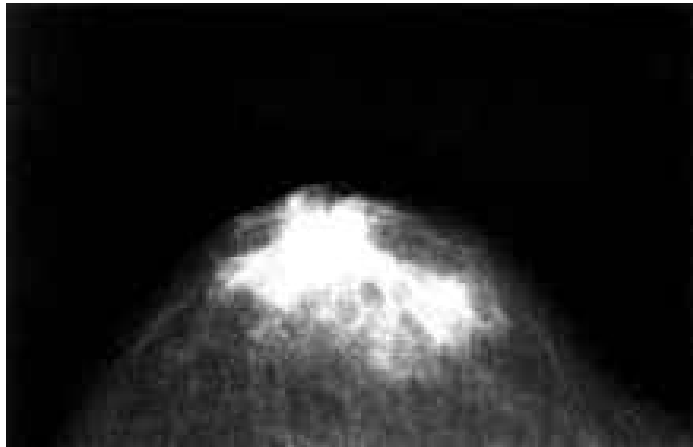
3. You see the relevant involutioon of the tumor.  
We have a normalization of all tumor-parameters.



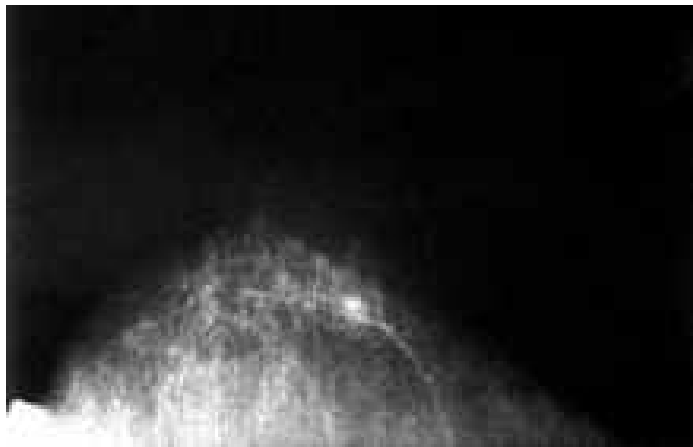1. Carcinoma of the breast left. The picture shows initial status with a tumordiameter of 3,6 cm



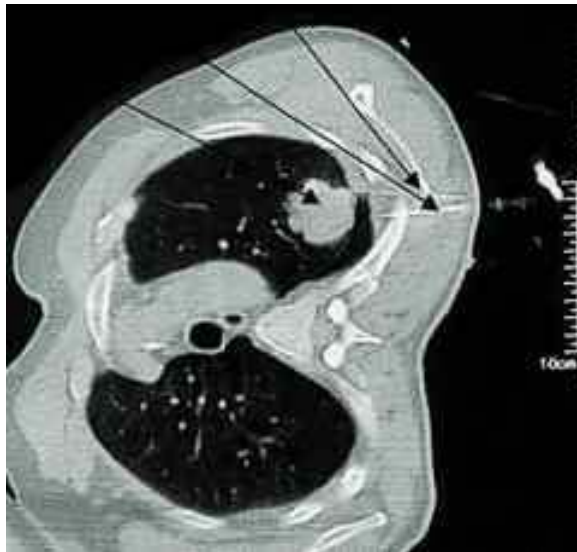2. After the treatment we see a relevant involution.



1. Scirrhous Carcinome of the breast.

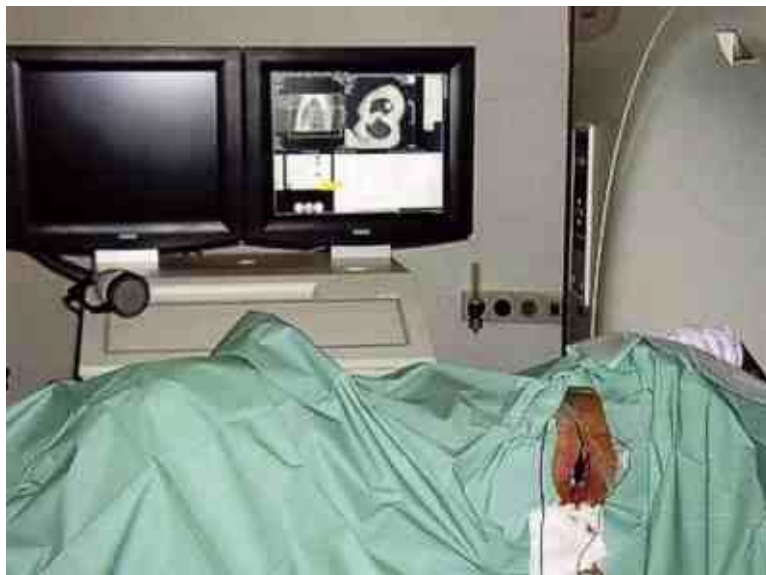

2. You see the complete healing after one year.



This roentgenogram shows a pulmonary tumor. The arrows shows distinct the tumor and the electrodes fort he Exogen-Elektronic-Therapie (EET).

The tumor is in involution. 1 ½ year after treatment the 48-year old patient feel very well he begins to make sport again.



In the foreground this picture shows the patient. On the right of the picture you can see the tube. In the background you can see the technical monitorequipment of the nuclear spin resonance tomography.